

Interactive CardioVascular and Thoracic Surgery

Extracorporeal life support in right ventricular rupture secondary to blast injury

Eleodoro Barreda, Erwan Flecher, Stéphane Aubert and Pascal Leprince

Interact CardioVasc Thorac Surg 2007;6:87-88; originally published online Oct 12, 2006;

DOI: 10.1510/icvts.2006.140814

The online version of this article, along with updated information and services, is located on the World Wide Web at:

<http://icvts.ctsnetjournals.org/cgi/content/full/6/1/87>

Interactive Cardiovascular and Thoracic Surgery is the official journal of the European Association for Cardio-thoracic Surgery (EACTS) and the European Society for Cardiovascular Surgery (ESCVS). Copyright © 2007 by European Association for Cardio-thoracic Surgery. Print ISSN: 1569-9293.

Proposal for bail-out procedures - Cardiac general Extracorporeal life support in right ventricular rupture secondary to blast injury

Eleodoro Barreda, Erwan Flecher, Stéphane Aubert*, Pascal Leprince

Department of Cardiothoracic Surgery, Institut du Coeur, Pitié Salpêtrière Hospital, University Pierre et Marie Curie, Paris, France

Received 31 July 2006; received in revised form 20 September 2006; accepted 21 September 2006

Abstract

Nowadays, indications of extracorporeal life support (ECLS) are increasing. We here describe a case of right ventricular rupture requiring challenging sutures. We installed an ECLS to re-establish the haemodynamic conditions and to discharge the ruptured right ventricle, permitting us to suture it.

© 2007 Published by European Association for Cardio-Thoracic Surgery. All rights reserved.

Keywords: Extracorporeal life support; Blast heart injury

1. Introduction

Recently, indications of extracorporeal life support (ECLS) have been reported [1]. We here describe an original indication of ECLS in a difficult case of heart injury.

2. Clinical summary

A 28-year-old man had a gunshot wound in the left upper chest. At the first clinical presentation he was conscious (Glasgow 15), but in haemorrhagic shock, without respiratory distress. The entrance point of the bullet was the fourth left intercostal space in the anterior axillary line and the exit point, with active bleeding, was the fifth right intercostal space. The chest X-ray showed a right pleural effusion, an enlargement of the cardiac silhouette and no evidence of intrathoracic bullet. The contrasted thoracic CT scan showed a sternal fracture, an extensive retrosternal haematoma, a right pulmonary contusion and pleural effusion, a limited pericardial effusion and a lack of contrast medium showing an active bleeding of the right mammary artery (Fig. 1).

After a median sternotomy the right mammary artery was ligated permitting to re-establish acceptable haemodynamic conditions. We removed a large right pleural effusion of blood. We found an extensive pulmonary contusion of medium and inferior pulmonary lobes. The pericardium was opened, showing a right ventricular dissecting haematoma in regard to the pulmonary infundibulum, which was bleeding. Firstly, we attempted to suture it by several pledgeted 4/0 Prolene® sutures without success, giving a progressive

right ventricular ripping. Secondly, a compression manoeuvre was attempted and was responsible for poor haemodynamic conditions. Then we put an ECLS between the right atrium and the ascending aorta. This system is a closed circuit based on a centrifugal pump (Rota Flow RF-32, Jostra Medizintechnik AG, Hirrlingen, Germany), and a hollow fibre membrane oxygenator (Quadrox D, Jostra Medizintechnik AG, Hirrlingen, Germany) with minimum priming volume (500 cc). All components are heparin surface coated. This surface treatment allows to use a simplified anticoagulation protocol. Considering the important bleeding, heparin was administered 6 h after the ECLS was activated, in continuous infusion. The activated clotting time (ACT) target was 120–180 s. This support re-established the haemodynamic conditions and discharged the ruptured right ventricle, permitting us to repair it efficiently. Total bleeding required 29 blood cell transfusions, 31 platelet units and 17 units of fresh plasma. The ECLS was removed on the fifth postoperative day. The patient was discharged 15 days after the ECLS removal without any sequelae.

3. Discussion

Treatment of dissecting haematoma of the right ventricle, especially with active bleeding, can be a real surgical challenge. To repair this kind of lesion using simple stitches, even if combined with Teflon® or pericardial pledgets, may be technically difficult. In this case, we performed an ECLS in order to decrease as much as possible the tension of the right ventricular wall. Not only did it allow an efficient repair, but also it was useful to quickly obtain satisfactory circulatory and respiratory conditions. During the following five days we left in place the ECLS to assure a satisfactory oxygenation in regard to the pulmonary contusion. ECLS can be used during several weeks, taking into account a

*Corresponding author. Department of Cardiovascular Surgery, Pitié Salpêtrière Hospital, 47-83 boulevard de l'hôpital, 75651 Paris Cedex 13, France. Tel.: +33 142165608; fax: +33 142165684.

E-mail address: stephaneaubert@yahoo.fr (S. Aubert).

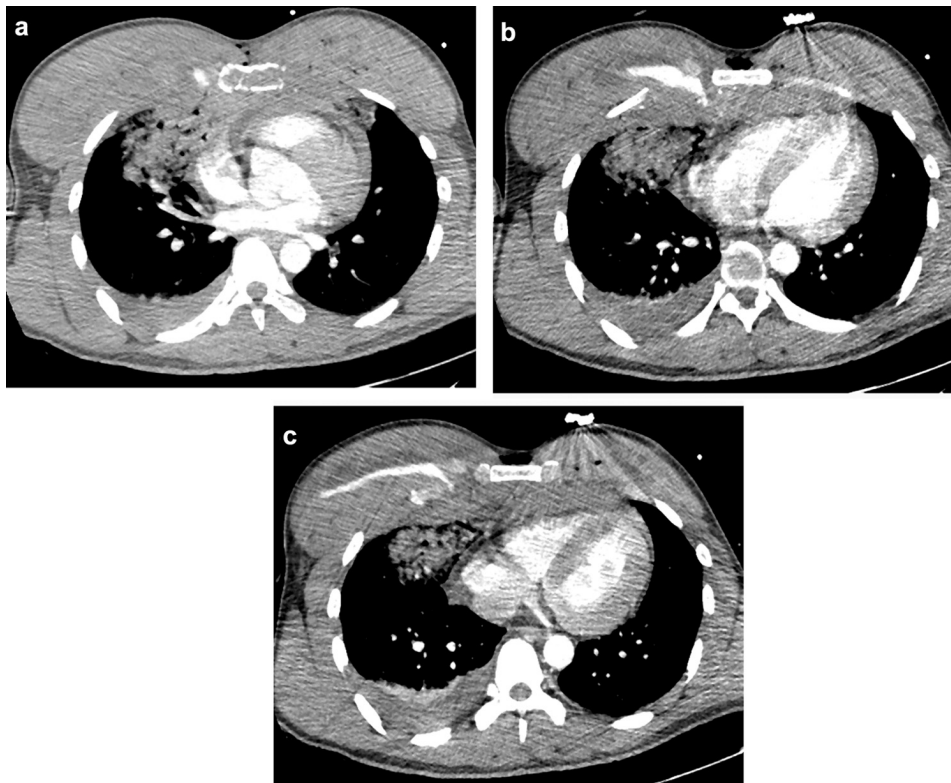


Fig. 1. Contrast thoracic CT scan. (a): Sternal fracture, extensive retrosternal haematoma, right pulmonary contusion and pleural effusion, limited pericardial effusion. (b) and (c): Lack of contrast medium showing an active bleeding of the right mammary artery.

regular change of the oxygenator membrane. Another argument in favour of this strategy was the postoperative questionable right ventricular function. Even if patch glue repair without extracorporeal circulation has been proposed in the case of free ventricular wall rupture, this technique has been applied using an aortic balloon pump to discharge the ventricle and does not seem applicable in massive and active bleeding [2]. Our approach is similar to what we have previously done in patients with left ventricular lesions requiring salvage sutures: rupture of the heart in massive infarction, large necrotic ventricular septal defect.

We believe that ECLS is useful in the case of right ventricular rupture requiring challenging sutures to achieve haemostasis.

References

- [1] Bartlett RH. Extracorporeal life support: history and new directions. *Asaio J* 2005;51:487-489.
- [2] Canovas SJ, Lim E, Hornero F, Montero J. Surgery for left ventricular free wall rupture: patch glue repair without extracorporeal circulation. *Eur J Cardiothorac Surg* 2003;23:639-641.

Extracorporeal life support in right ventricular rupture secondary to blast injury

Eleodoro Barreda, Erwan Flecher, Stéphane Aubert and Pascal Leprince

Interact CardioVasc Thorac Surg 2007;6:87-88; originally published online Oct 12, 2006;

DOI: 10.1510/icvts.2006.140814

This information is current as of December 11, 2007

**Updated Information
& Services**

including high-resolution figures, can be found at:
<http://icvts.ctsnetjournals.org/cgi/content/full/6/1/87>

References

This article cites 2 articles, 1 of which you can access for free at:
<http://icvts.ctsnetjournals.org/cgi/content/full/6/1/87#BIBL>

Permissions & Licensing

Requests to reproducing this article in parts (figures, tables) or in its entirety should be submitted to: icvts@ejcts.ch

Reprints

For information about ordering reprints, please email:
icvts@ejcts.ch

Interactive CardioVascular and Thoracic Surgery